

STUDIES OF CLINICAL SIGNS AND HEMATOLOGICAL ALTERATIONS IN JAPANESE QUAILS (*Coturnix japonica*) DUE TO *Toxoplasma gondii* NICOLLE AND MANCEAUX, 1909 (APICOMPLEXA: TOXOPLASMATINAE) EXPERIMENTAL INFECTION*

ALEXANDRE D. MUNHOZ¹; GEORGE R. ALBUQUERQUE¹; FRANCISCO C. R.
DE OLIVEIRA²; CARLOS W. G. LOPES³

ABSTRACT:- MUNHOZ, A. D.; ALBUQUERQUE, G.R.; OLIVEIRA, F.C.R. DE; LOPES, C.W.G. **Studies of clinical signs and hematological alterations in Japanese quails (*Coturnix Japonica*) due to *Toxoplasma gondii* Nicolle and Manceaux, 1909 (Apicomplexa: Toxoplasmatinae) experimental infection** [Estudo das alterações clínicas e hematologia na infecção experimental em codornas japonesas (*Coturnix japonica*) por *Toxoplasma gondii* Nicolle e Manceaux, 1909 (Apicomplexa: Toxoplasmatinae)]. *Revista Brasileira de Parasitologia Veterinária*, v. 13, n. 1, p. 1-5, 2004. Departamento de Parasitologia Animal, Instituto de Veterinária, Universidade Federal Rural do Rio de Janeiro, Seropédica, RJ 23890-000, Brazil. E-MAIL: lopescwg@ufrj.br

One hundred and ten quails (*Coturnix japonica*) were used in this experiment, and each quail was thirty days old. They were divided into four groups. The quails of groups A and B were inoculated subcutaneously with 10^6 and 10^4 tachyzoites of Sero-47 *Toxoplasma gondii* strain, respectively, and animals of group C that were inoculated with 10^5 tachyzoites of 'P' strain of the same parasite. The quails of the last group (D) received just saline, and they were left as control. The groups A, B and C had thirty birds each, while group D had only twenty birds. The body weight and temperature was verified from the zero to the 21st DAI (days after infection). The blood samples used to realize the hemograms were collected on the 1st, 3rd, 7th, 14th, 21st, and 70th days from the groups A, B, and D, and on 3rd, 7th, 14th and 70th days DAI from group C, always using five birds from each group. Only one bird in group C died, while two birds, one of group A, and another of group C showed prostration and incoordination. Hyperthermia was observed on the 13th and 20th DAI in group C. Birds infected with 'P' strain had normocytic and normochromic anemia in the 7th DAI presenting leukopenia, lymphopenia, and monocytosis, while the group infected with Sero-47 strain had leukopenia with heteropenia, and monocytosis. Fibrinogen values remained high from the 3rd to the 21st DAI in all groups. It is concluded in the presented work, that the 'P' strain caused alteration in the hemogram in the majority of the quails. Independently of the strain used, animals showed subclinical evolution of this infection.

KEY WORDS: Toxoplasmosis, Japanese quails, clinical signals, hematology, experimental infection.

RESUMO

Cento e dez codornas (*Coturnix japonica*) foram usadas neste experimento, onde cada codorna tinha 30 dias de idade.

*Supported by CNPq.

¹Curso de Pós-Graduação em Ciências Veterinárias, Universidade Federal Rural do Rio de Janeiro (UFRRJ), BR 465, Km 7, 23890-000, Seropédica, RJ e DCAA, Universidade Estadual de Santa Cruz (UESC), Ilhéus, BA. E-mails: munhoz@uesc.br and georgealbu@ig.com.br

²Laboratório de Sanidade Animal, CCTA, Universidade Estadual do Norte Fluminense (UENF), Campos dos Goytacazes, RJ. E-mail: foliveira@uenf.br

³Departamento de Parasitologia Animal, Instituto de Veterinária, UFRRJ, 23890-000, Seropédica, RJ, Brasil. E-mail: lopescwg@ufrj.br

Estas foram divididas em quatro grupos. As codornas dos grupos A e B foram inoculadas com 10^6 e 10^4 taquizoítas da cepa Sero-47 e as do grupo C com 10^5 a cepa 'P' do *Toxoplasma gondii* respectivamente, por via subcutânea, cada grupo constituído por 30 codornas. As codornas do grupo D, constituído por 20 animais, receberam somente solução salina e assim consideradas como controle. O peso e a temperatura corporal foram verificados do dia zero ao 21^o dia após infecção (DAI). As amostras de sangue usadas para os hemogramas das aves foram coletadas nos dias 1^o, 3^o, 7^o, 14^o, 21^o e 70^o DAI dos grupos A, B, e D, e no 3^o, 7^o, 14^o e 70^o DAI do grupo C, sempre usado cinco codornas de cada grupo.

Somente um animal morreu, do grupo C, enquanto duas codornas, uma do grupo A e outra do grupo C tiveram prostração e incoordenação. Hipertermia foi observada aos 13° e aos 20° DAI no grupo C. Codornas infectadas com a cepa 'P' tiveram anemia normocítica e normocrômica aos 70° DAI, tiveram, ainda, leucopenia, linfopenia e monocitose. Valores de fibrinogênio mantiveram-se altos do 3 ao 21 DAI em todos os grupos. No presente trabalho observou-se que a cepa 'P' de *T. gondii* foi responsável pelas variações no hemograma das codornas. Independentemente da cepa utilizada, as codornas infectadas tiveram evolução subclínica da doença.

PALAVRAS-CHAVE: Toxoplasmose, codornas japonesas, sinais clínicos, hematologia, infecção experimental.

INTRODUCTION

Toxoplasmosis is a disease caused by *Toxoplasma gondii*. It is considered as one of the most studied zoonosis of the world, as researchers try to elucidate some existing doubts about their biology, pathogenicity, and distribution, in order to improve the knowledge about the disease, and its etiological agent.

A big finding related to the parasite was the elucidation of its life cycle by Frenkel et al. (1970), being felines as its final host. Its pathogenicity is directly related to their strains and parasited hosts. Beverly (1976) suggested that the majority of the existing strains in nature is considered of having low virulence and less pathogenicity to their hosts.

Natural and experimental infections in some birds had demonstrated subclinical evolution without clinical signs compatible to Toxoplasmosis, transforming their intermediate hosts, or those animals which have been used in bird production for the consumption of animals and humans (DUBEY; BATTIE, 1988), and as important reservoir of *T. gondii* in nature (PEIXOTO; LOPES, 1991; DUBEY et al., 2003a,b).

The purpose of this investigation is to determine clinical signals and hematological alterations due to *T. gondii*, using two strains: Sero-47 and "P" in Japanese quails.

MATERIALS AND METHODS

This experiment was done at W.O.NEITZ Experimental Station, Departamento de Parasitologia Animal, Instituto de Veterinária in Universidade Federal Rural do Rio de Janeiro (UFRRJ), City of Seropédica, State of Rio de Janeiro (RJ), Brazil.

Origin of *Toxoplasma gondii* Strains. Tachyzoites of Sero-47 strain were isolated from free range chickens by Medeiros and Lopes (1996), and 'P' strain were obtained at Center for Parasitological Research (CPPAR), UNESP/FCAV, City of Jaboticabal, State of São Paulo, Brazil. Both strains were maintained at the Department of Animal Parasitology until the end of the experiment.

Origin of Japanese quails. One hundred and ten thirty days old birds, all females, came from a hatchery placed in

the Municipality of Petrópolis, RJ. The birds were kept in properly cages a week before the experiment for adaptation. They were fed with quail commercial food every day and had water *ad libitum*.

***Toxoplasma gondii* inocula.** After washing the peritoneal cavity of albino mice, previously inoculated with *T. gondii* strains, the exsudate containing the tachyzoites of the parasite was removed. It was centrifuged at 500 G for a period of 10 minutes. The supernatant was, then, removed and placed in another tube, where it was centrifuged at 2000 G during 10 minutes. The sediment was resuspended in saline solution at 0.9 %. After that, small samples equivalent to 0.002 ml were removed from the solution. All the tachyzoites found in these samples were counted at Neubauer's chamber in order to obtain final aliquots of 10⁴ and 10⁶ tachyzoites of Sero-47, and 10⁵ tachyzoites of "P" strain. Both were *T. gondii* strains.

Experimental design. Birds were randomly distributed into four groups. Two groups (A and B), consisted by 30 birds each, were infected with Sero-47 strain. Group A received 10⁶ and group B, 10⁴ tachyzoites. Group C was infected by 10⁵ 'P' strain tachyzoites, and was consisted by 20 birds, while group D, also consisted by 30 birds, was inoculated with saline solution subcutaneously, and it was left as control.

Clinical Laboratory evaluation of the birds. Cloacal temperature and body weight of all birds were verified from the zero to the 21st DAI in the morning. Blood samples were collected from groups A,B and D on the first, 3rd, 7th, 14th, 21st and 70th DAI, and on the 3rd, 7th, 14th and 70th DAI from group C. Five birds were bled in each day, and blood was put into tubes containing EDTA at 11%. Determination of red blood cell (RBC), white blood cell (WBC), and hemoglobin concentration (HC) was realized according to Almosny et al. (1998), based on birds' blood cells differentiation (CAMPBELL, 1988). Packet Cells Volume (PCV), total plasmatic protein (TPP) and fibrinogen (F), and Hematimetric index were determined according to Coles (1984). Blood smears were done to verify specific leukometry keeping the smears in methanol for three minutes and staining in three drops/ml of Giemsa, for 15 minutes.

Statistics analysis. Tukey's test was used to do the analysis, with a level significance of 95%, according Sampaio (2002).

RESULTS AND DISCUSSION

Clinical signals. Among the quails of group B, none of them presented any clinical manifestation according to the infection. In-group C one bird was found dead on the 8th DAI, and another, on the 9th DAI showed ruffled feathers, incoordination, and prostration. Similar symptoms were observed on the 18th DAI in a bird from group A (Tab. 1). The predominance of an asymptomatic situation was similar to those observed by Flausino et al. (2000) in Japanese quails inoculated with Sero-47 strain, and those pointed out by Kaneto et al. (1997) in broiled chickens inoculated with 'P' strain. However, the GT-1 strain was fatal to Japanese quails, while ME-49 strain of the same parasite, demonstrated low

Table 1. Behavior of quails experimentally infected with *Toxoplasma gondii* tachyzoites subcutaneously.

Groups	Strain of the parasite	Infected Doses	Animals	
			Clinical signals	Mortality
A	Sero-47 ^a	10 ⁶	0/30	0/30
B	Sero-47 ^b	10 ⁴	1/30 (3,34) ^a	0/30
C	"P"	10 ⁵	1/20 (5.00)	1/20 (5.00)
D	Controls	Saline	0.20	0/20

^a Percentage in parenthesis.

mortality, both results according to Dubey et al. (1994). Comparing these results, the resistance of these birds to the infection could depend of the strain, and not necessarily to the *inoculum*, being pathogenic or not (BEVERLY, 1976).

Cloacal temperature. During the experiment the increase of the temperature was observed on the 13th and 20th DAI in birds of group C. Despite of being 'P' or Sero-47 strain, the temperature had values over to those observed in control birds, but these values were maintained between the proper limits of Japanese quails. These results were similar to those observed by Kaneto et al. (1997) in broiled chickens, where hyperthermia, in early infection, was a common finding.

Body weights. In the infected groups it was not observed the reduction on the daily body weight gain in relation to controls. This result was similar to that observed by Flausino et al. (2000) as they used 10³ tachyzoites of Sero-47. In spite of this strain, it was isolated in free range chickens (MEDEIROS; LOPES, 1996).

Red Blood Cell. All infected groups, with the exception of group A, had progressive reduction in RBC mean values from the beginning of the experiment to the 7th DAI. In these days, groups A and B were significant (P<0.05) and group C had P<0.01 in relation to group D. Being that, only in the group C, RBC was below the reference band. After 14th DAI these values increased, getting near to group D until the final of the experiment (Fig. 1). These findings were similar to those observed by Kaneto et al. (1997) in which broiled chickens were infected with 'P' strain of *T. gondii*.

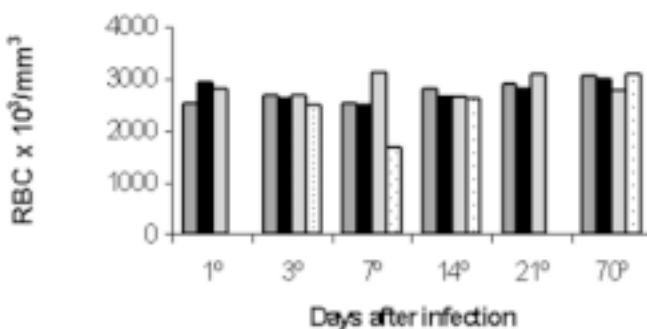


Figure 1. Red blood cells mean values observed in quails infected experimentally with 10⁴ (—) e 10⁶ (—) tachyzoites of the strain Sero-47, 10⁵ (•••) of the strain 'P' of *Toxoplasma gondii* and control group (—).

Hemoglobin. Mean concentration values of groups A and B were similar to those found in-group D, during the entire experiment. This result was not observed in-group C, because on the 7th DAI a significant reduction (P<0.01) was observed. Similar values to other groups were shown after the 14th DAI (Fig. 2). With exception of the 70th DAI, all groups showed values below the reference band. These results were similar to those pointed out by Kaneto et al. (1997).

Packet Cell Volume. On the first DAI the mean PCV values of group A were lower than those of group D (P<0.01). On the 7th DAI, all groups showed a significant reduction in their values, groups A and B (P<0.05), and group C (P<0.01), showing that these values were out of the reference band. From the 14th DAI until the final of the experiment, the PCV values of the infected animals stayed close to those observed in group D (Fig. 3).

Hematimetric indexes. In spite of the means of corpuscular volume (MCV), corpuscular hemoglobin (MHC), and corpuscular hemoglobin concentration (MCHC), changes observed during the experiment, these obtained values were close to the reference band. The observed anemic pictures during the experiment were classified as normocytic and normochromic anemia in comparison with group D. In the red series, the majority of changes occurred on the seventh DAI, mainly in Japanese quails from group C.

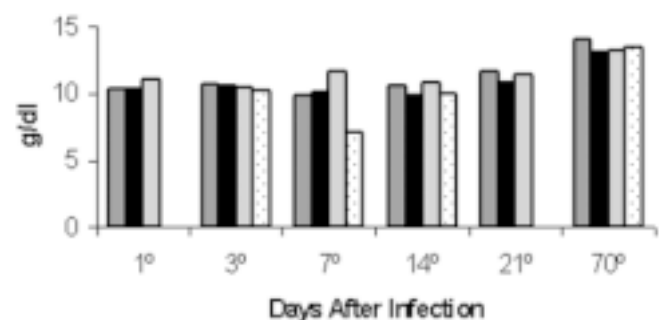


Figure 2. Hemoglobin mean values observed in quails infected experimentally with 10⁴ (—) e 10⁶ (—) tachyzoites of the strain Sero-47, 10⁵ (•••) of the strain 'P' of *Toxoplasma gondii* and control group (—).

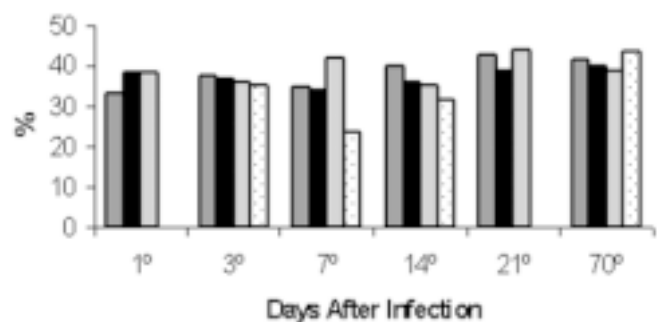


Figure 3. Packet cell volume mean values observed in quails infected experimentally with 10⁴ (—) e 10⁶ (—) tachyzoites of the strain Sero-47, 10⁵ (•••) of the strain 'P' of *Toxoplasma gondii* and control group (—).

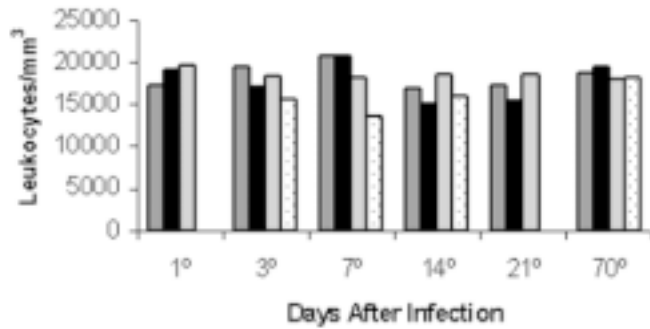


Figure 4. Total leukometry mean values observed in quails infected experimentally with 10^4 (□) e 10^6 (■) tachyzoites of the strain Sero-47, 10^5 (●●) of the strain 'P' of *Toxoplasma gondii* of *Toxoplasma gondii* and control group (—).

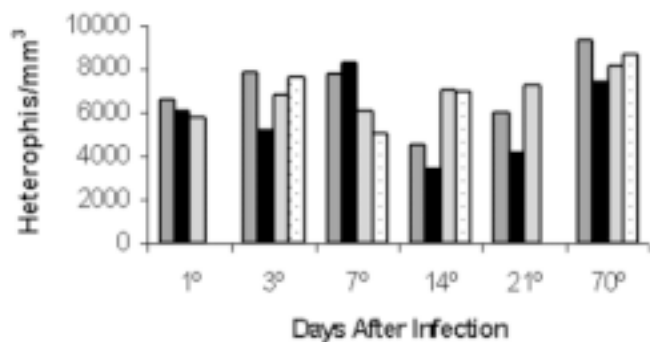


Figure 5. Heterophils mean values observed in quails infected experimentally with 10^4 (□) e 10^6 (■) tachyzoites of the strain Sero-47, 10^5 (●●) of the strain 'P' of *Toxoplasma gondii* and control group (—).

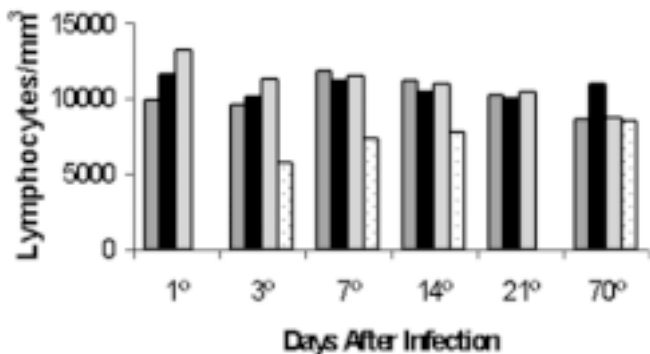


Figure 6. Lymphocytes mean values observed in quails infected experimentally with 10^4 (□) e 10^6 (■) tachyzoites of the strain Sero-47, 10^5 (●●) of the strain 'P' of *Toxoplasma gondii* e control group (—).

White Blood Cell. An increase of WBC mean values was observed in groups A and B on the 7th DAI, but on the 14th and 21st DAI, both groups showed reduction in the number of leukocytes. Group B values were below the reference band ($P < 0.05$), being characterized as a leukopenic picture. Leukopenia was observed in-group C from the 3rd to 14th DAI, but it was significant on the seventh DAI in comparison with group D (Fig. 4). These results demonstrated that birds

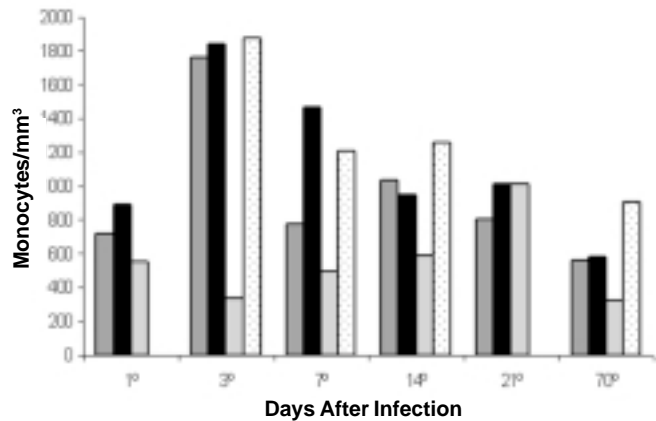


Figure 7. Monocytes mean values observed in quails infected experimentally with 10^4 (□) e 10^6 (■) tachyzoites of the strain Sero-47, 10^5 (●●) of the strain 'P' of *Toxoplasma gondii* e control group (—).

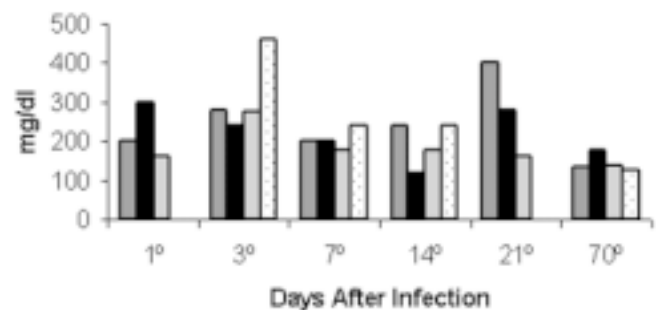


Figure 8. Fibrinogen mean values observed in quails infected experimentally with 10^4 (□) e 10^6 (■) tachyzoites of the strain Sero-47, 10^5 (●●) of the strain 'P' of *Toxoplasma gondii* and control group (—).

infected by 'P' strain had a quickly leukopenic picture when compared with those infected by Sero-47 strain of *T. gondii*.

Heterophils. The mean values of groups A and B increased on the 7th DAI, being group B value significant ($P < 0.05$). On the 14th and 21st DAI, both groups had Heterophils values reduced significantly, being ($P < 0.01$) to group B and $P < 0.05$ to group A. This heteropenia was responsible for the reduction in WBC of both groups. It was observed a greater reduction in the heterophils mean values in-group C on the 7th DAI, which contributed to the observed leukopenia on this day (Fig. 5).

Lymphocytes. The mean values of groups A and B were similar to those observed from group D. However, in relation to group C, absolute lymphopenia was observed on the 3rd and 14th DAI ($P < 0.05$). This lymphopenia was probably responsible for leukopenia in group C (Fig. 6).

Monocytes. Increase of monocytes mean values ($P < 0.05$) was observed in infected groups from the 3rd to the 14th DAI in groups A and B and until the 70th DAI in group C (Fig. 7) in comparison with group D.

Eosinophiles. The mean values observed in the whole experiment persisted, independent of Groups A, B, C, and D, were the same as the references values for birds.

Fibrinogen. Mean values in infected groups were higher in comparison to the control group from the first to the 21st DAI in groups A and B, and from the 3rd to the 14th DAI in group C. The higher values in groups A and B were observed on the 21st DAI ($P < 0.05$), while in group C it was observed on the 3rd DAI (Fig. 8). According to Hawkey and Hart (1988), birds with bacterial infection, hyperfibrinogenaemia was verified in 63% of the cases reported. In spite of observed results in this investigation, few is known about these results in bird due to *T. gondii* infection.

Total plasmatic proteins. Mean values of TPP in group A increased on the 7th and on the 14th DAI, and those of group C decreased on the 14th and on the 70th DAI in comparison to group D. In group B results were similar to those of group D. Results were similar to those observed by Atwal et al. (1964) in which values above 5.6 g/dl were related in female quails, an increase of circulate lipids, that interfered in the plasmatic refraction.

Being that, clinical signals were characterized by prostration, incoordination and hyperemia where "P" strain was associated to more alterations in the hemogram in the majority of the quails in comparison to SERO-47 strain of the parasite. Independently of the strain used, all experimented infected Japanese quails showed subclinical evolution during the experimental infection.

BIBLIOGRAFIC REFERENCES

- ALMOSNY, N.R.P.; PAULA SILVA, K. de; SILVA MELO, D.L. da; VASCONCELOS, T.C.; MONTEIRO, A.O. Hematologia de aves: valores normais em hemograma de mutum de Alagoas (*Mitu mitu*). *Revista Brasileira de Ciência Veterinária*, v. 5, n. 3, p. 119-122, 1998.
- ATWAL, O.S.; MCFARLAND, L.Z.; WILSON, W.O. Hematology of *Coturnix* from birth to maturity. *Poultry Science*, v. 43, n. 6, p. 1392-1401, 1964.
- BEVERLEY, J.K. Toxoplasmosis in animals. *Veterinary Record*, v. 99, n. 7, p. 123-127, 1976.
- CAMPBELL, T.W. Fish cytology and Hematology. *Veterinary Clinical of North American: Small Animals Practice*. v. 18, p. 349-364, 1988.
- COLES, E.H. *Patologia clínica veterinária*. 3^a ed. Rio de Janeiro: Manole, 1984, 566 p.
- DUBEY, J.P.; BEATTIE, C.P. *Toxoplasmosis of animals and man*. Boca Raton: CRC Press, 1988. 220 p.
- DUBEY, J.P.; GOODWIN, M.A.; RUFF, M.D.; KWOK, O.C.H.; SHEN, S.K.; WILKINS, G.C.; THULLIEZ, P. Experimental toxoplasmosis in Japanese quail. *Journal of Veterinary Diagnostic Investigation*, v. 6, n. 2, p. 216-221, 1994.
- DUBEY, J.P.; NAVARRO, I.T.; GRAHAM, D.H.; DAHL, E.; FREIRE, R.L.; PRUDÊNCIO, L.B.; SREEKUMAR.C.; VIANNA, M.C.; LEHMANN, T. Characterization of *Toxoplasma gondii* isolates from free range chickens from Paraná, Brazil. *Veterinary Parasitology*, v. 117, n. 3, p. 229-234, 2003a.
- DUBEY, J.P.; GRAHAM, D.H.; SILVA, D.S., LEHMANN, T.; BAHIA-OLIVEIRA, L.M.G. *Toxoplasma gondii* isolates of free-ranging chickens from Rio de Janeiro, Brazil. *Journal of Parasitology*, v. 89, n. 4, p. 851-853, 2003b.
- FLAUSINO, W.; ALBUQUERQUE, G.; MUNHOZ, A.D.; LOPES, C.W.G. Infecção experimental em codornas (*Coturnix coturnix japonica*) com *Toxoplasma gondii* Nicolle e Manceaux, 1909. *Revista Universidade Rural, Ciências da Vida*, v. 22, supl 1, p. 91-94, 2000.
- FRENKEL, J.K.; DUBEY, J.P.; MILLER, N.I. *Toxoplasma gondii*: fecal stages identified as coccidian oocysts. *Science*, v. 167, n. 919, p. 893-896, 1970.
- HAWKEY, C.; HART, M.G. An analysis of the incidence of hyperfibrinogenaemia in birds with bacterial infection. *Avian Pathology*, v. 17, n. 2, p. 427-432, 1988.
- HULDT, G. Experimental toxoplasmosis. Effect of inoculation of *Toxoplasma* in seropositive rabbits. *Acta Pathologica and Microbiologica Scandinavica*, v. 68, n. 4, p. 592-604, 1966.
- KANETO, C.N.; COSTA, A.J. da; PAULLILO, A.C.; MORAES, F.R.; MURAKAMI, T.O.; MEIRELLES, M.V. Experimental toxoplasmosis in broiler chickens. *Journal of Parasitology*, v. 69, n. 3-4, p. 203-310, 1997.
- MEDEIROS, S.M. de; LOPES, C.W.G. Pleomorfismo de uma amostra acistogênica de *Toxoplasma gondii* Nicolle & Manceaux, 1909 (Apicomplexa: Toxoplasmatinae). *Revista Brasileira de Medicina Veterinária*, v. 18, n. 2, p. 71-73, 1996.
- PEIXOTO, C.M.S.; LOPES, C.W.G. Isolamento do *Toxoplasma gondii* Nicolle & Manceaux, 1909 (Apicomplexa: Toxoplasmatinae) em galinhas naturalmente infectadas. *Arquivos da Universidade Federal Rural do Rio de Janeiro*, v. 13, n.2, p. 105-111, 1991.
- SAMPAIO, I.B.M. *Estatística aplicada à experimentação animal*. 2^a Ed. Belo Horizonte: Fundação de Estudo e Pesquisa em Medicina Veterinária e Zootecnia, 2002. 265p.

Recebido em 11 de novembro de 2003.

Aceito para publicação em 29 de dezembro de 2003.